



HOW TO DEAL WITH VARUS

Childhood specificity

Drs Nicolas GRAVELEAU, Nicolas BOUGUENNEC, Antoine MORVAN & Pierre LABOUDIE

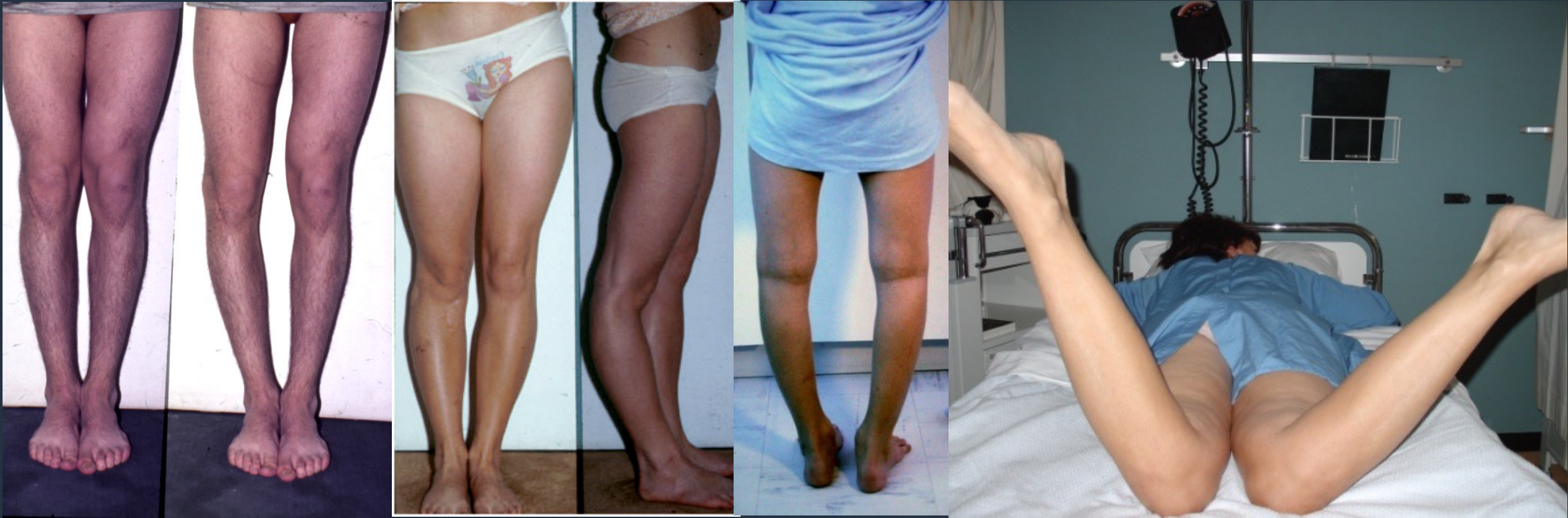Centre du genou sportif- Bordeaux-Mérignac ,Nouvelle-Aquitaine, France

Thanks to Pr Thomas NERI, Pr Matthieu OLLIVIER, Pr Sébenstien PESENTI ,Pr Raphael VIALLE & Dr Mathilde GAUME

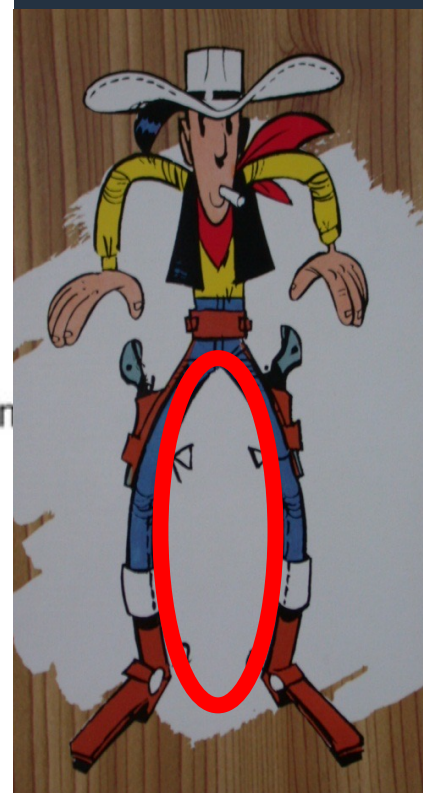
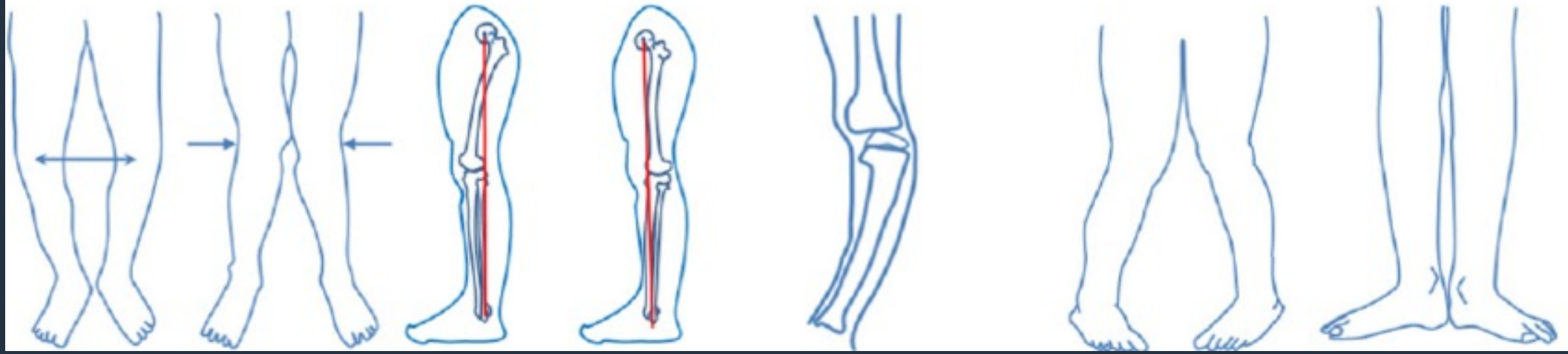
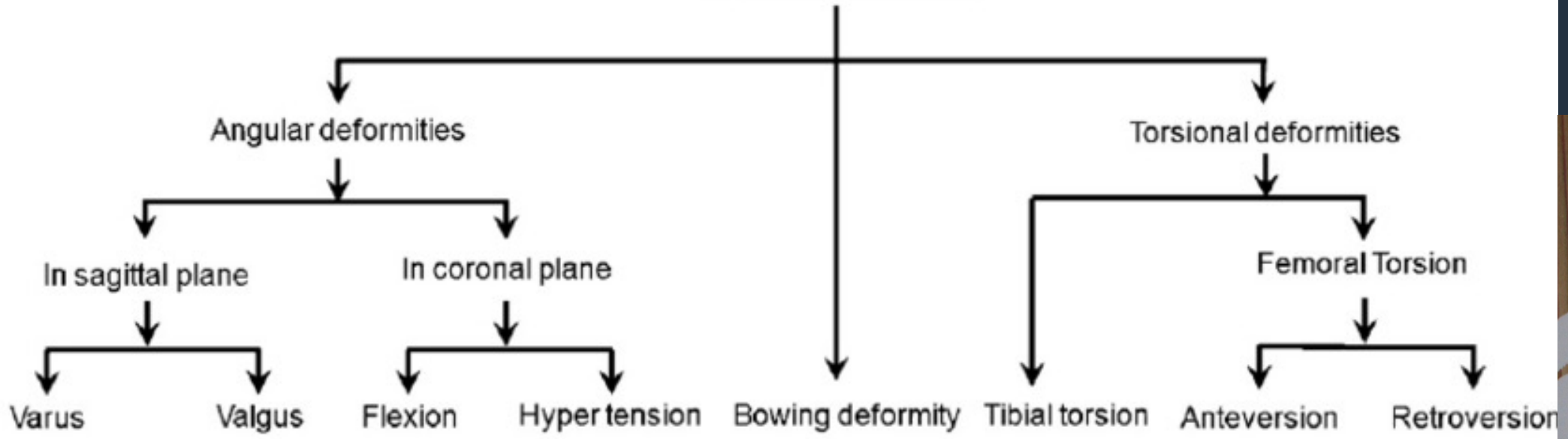
Ciao Pierrot



MORPHOTYPE ABNORMALITIES IN CHILDHOOD



Lower limb deformities



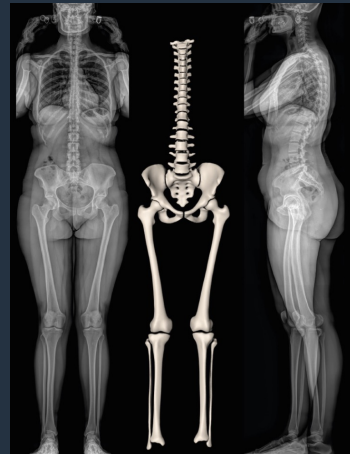
INTRODUCTION

Complex notion of "normality"

Ancient study => Few cases

Recent Big Data Scanner Study

Interest of EOS (radiation)



Knee Surgery, Sports Traumatology, Arthroscopy
<https://doi.org/10.1007/s00167-019-05524-0>

KNEE

Check for updates

Contralateral preoperative templating of lower limbs' mechanical angles is a reasonable option

Christophe Jacquet^{1,2} · Pierre Laumonerie^{3,4} · Sally LiArno⁵ · Ahmad Faizan⁵ · Akash Sharma^{1,2} · Louis Dagneaux^{1,2} · Matthieu Ollivier^{1,2}

Received: 15 November 2018 / Accepted: 29 April 2019
© European Society of Sports Traumatology, Knee Surgery, Arthroscopy (ESSKA) 2019

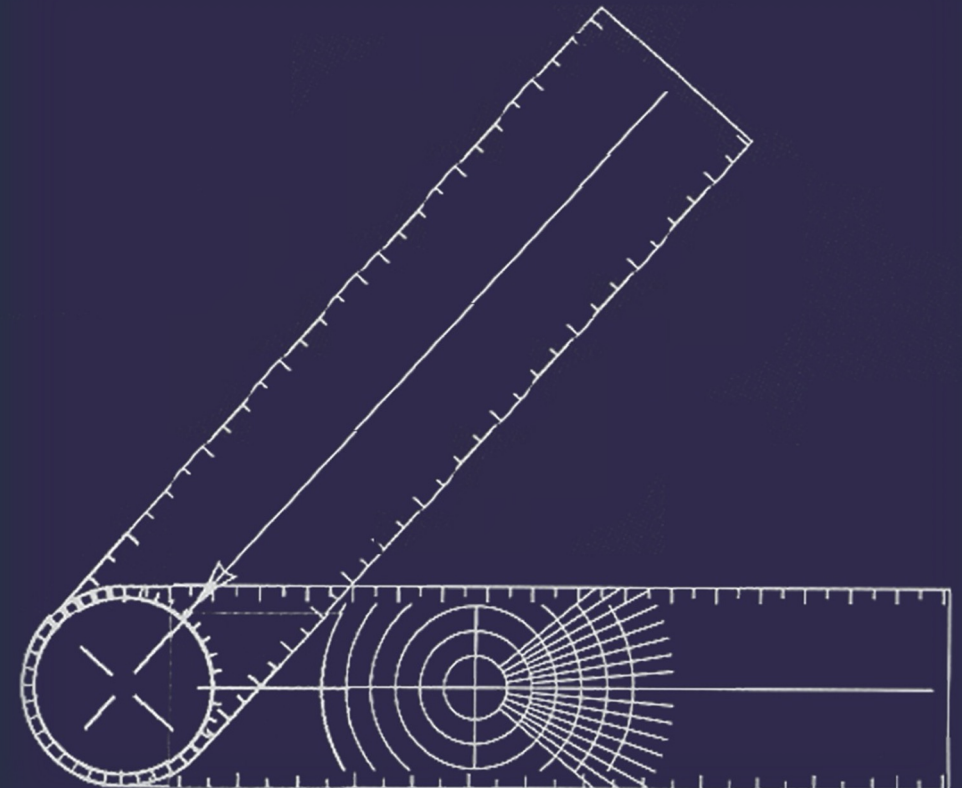
AO Foundation
Publishing

Editors: Philippe Lobenhoffer, Rüdiger von Stechow, Alex C. Sanchis, Roland F. Jauch
Co-editor: Matthew Galla, Jan D. Aigner-Korner

Osteotomies around the Knee

Indication—Planning—Surgical Techniques using Plate Fixators

Thieme

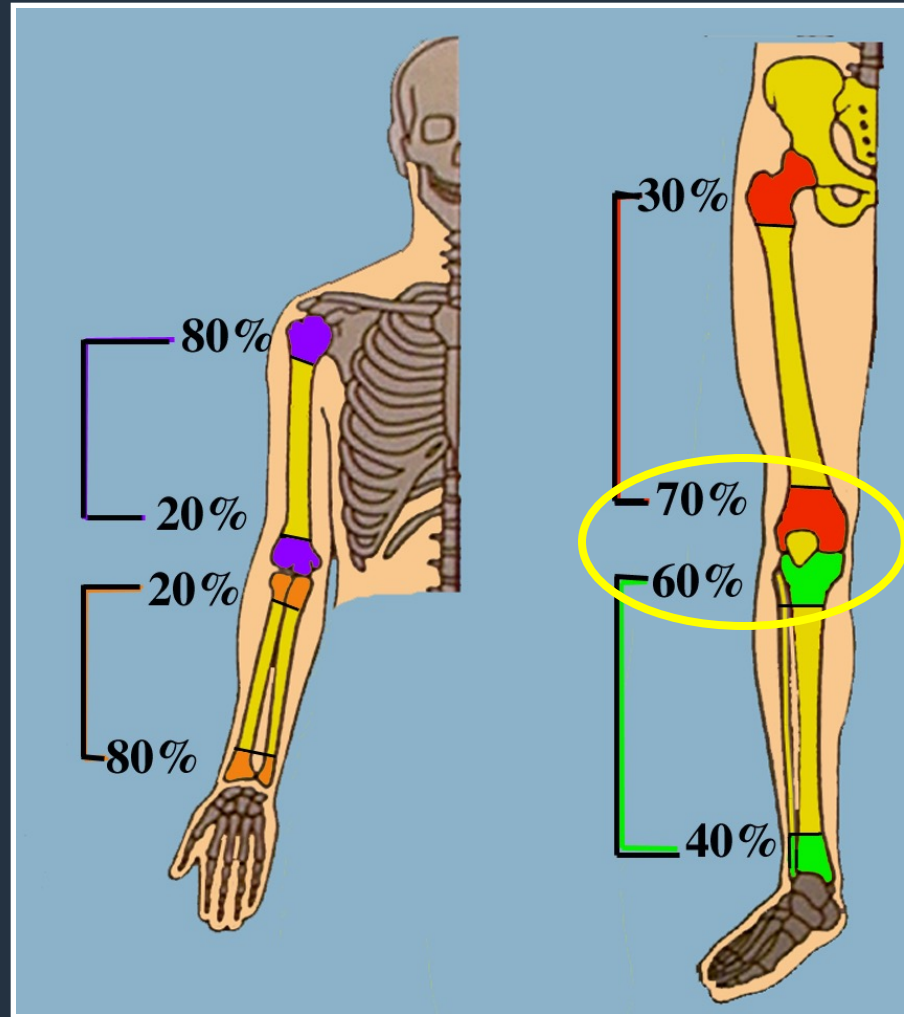


Long bone growth

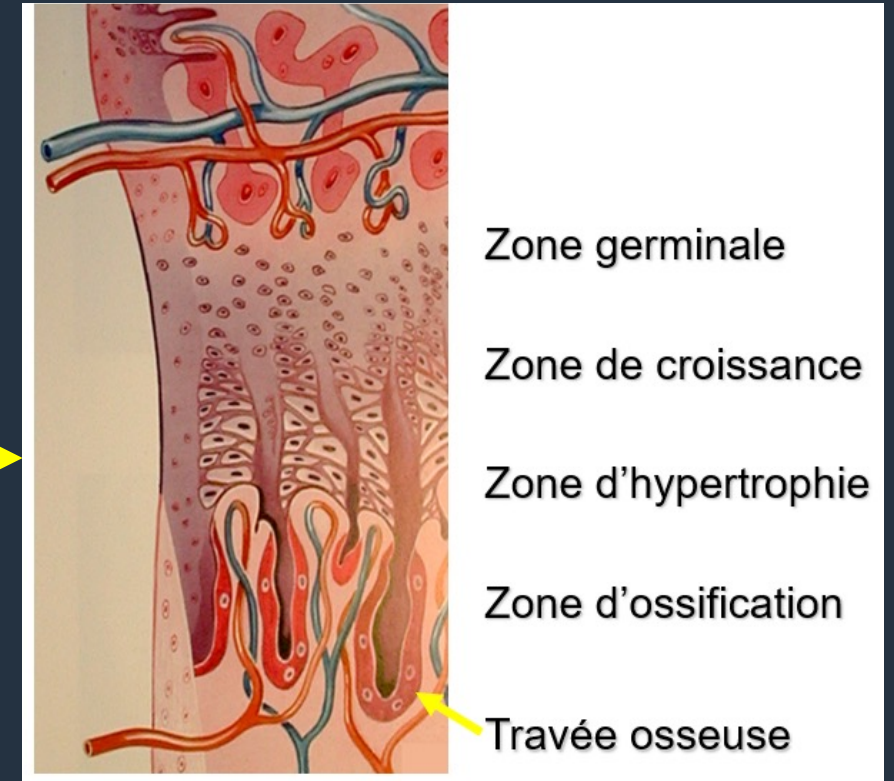
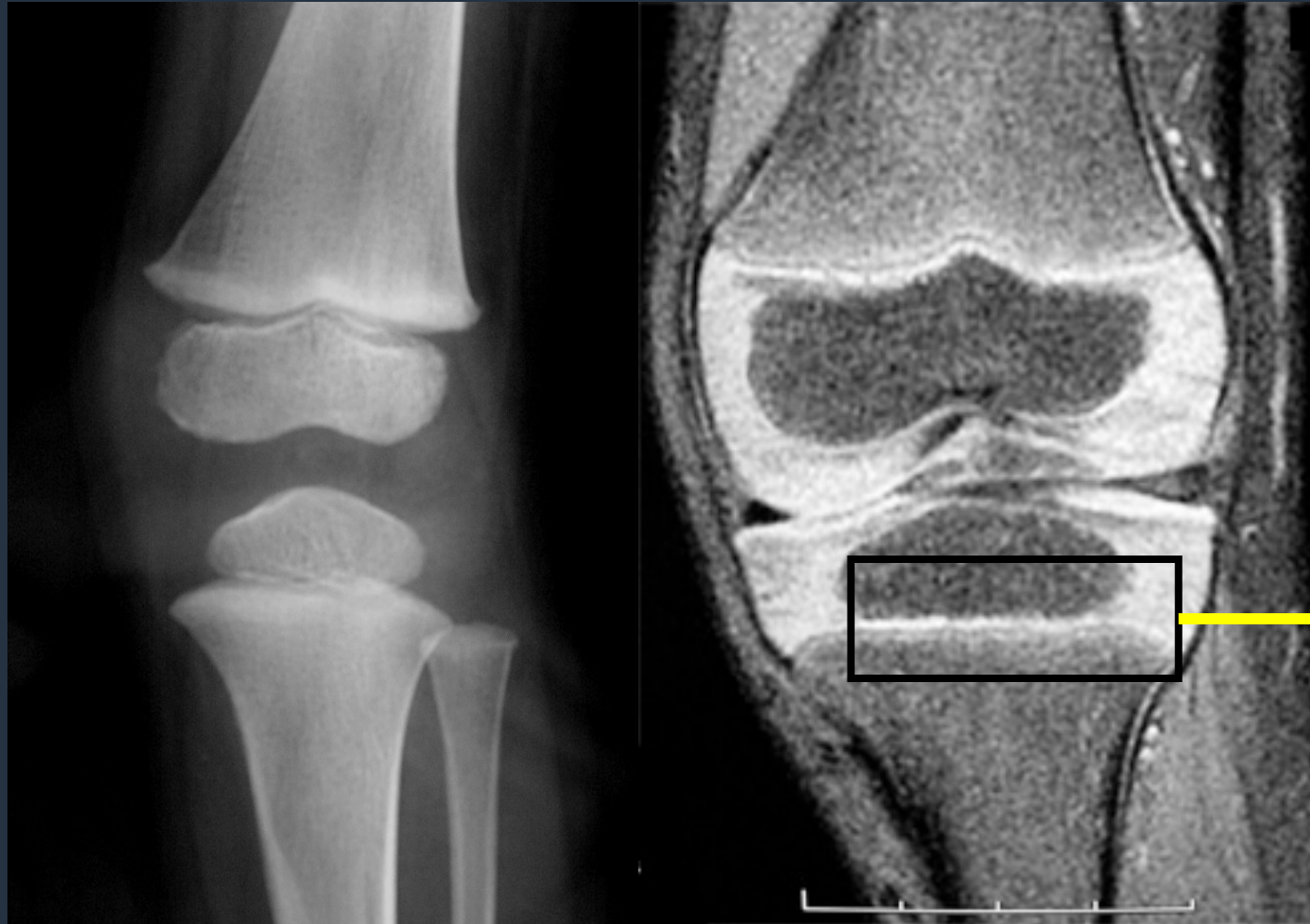- Away from Elbow

- Close to the knee

- 70 % of the femur
- 60 % of the tibia



GROWTH AROUND THE KNEE



Appearance of Knee Growth Cartilage in Radiology and MRI

MORPHOTYPE ABNORMALITIES IN CHILDHOOD

"NORMAL" MORPHOMETRY

CORONAL MORPHOLOGICAL ABNORMALITY

SAGITTAL MORPHOLOGICAL ABNORMALITY

TORSIONAL MORPHOLOGICAL ABNORMALITY

CLINICAL EXAMINATION

Bilateral Comprehensive Clinical Examination

Global Lower Extremity Alignment

Dynamic assessment achieves of:

- Ligament stabilizers
- Musculotendinous
- Meniscus
- Cartilage

Increases deformation

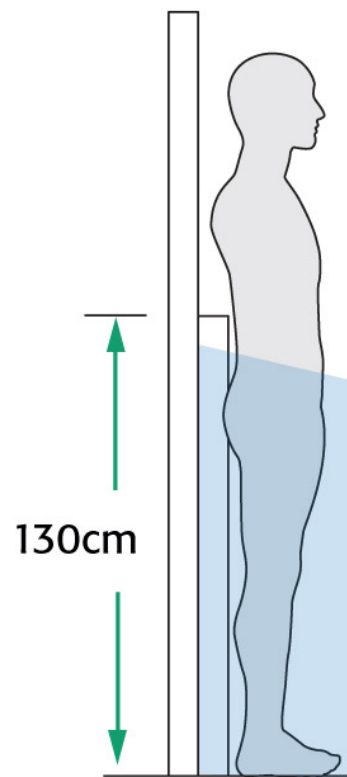
NATURAL EVOLUTION OF THE FRONTAL MORPHOTYPE

3 phases

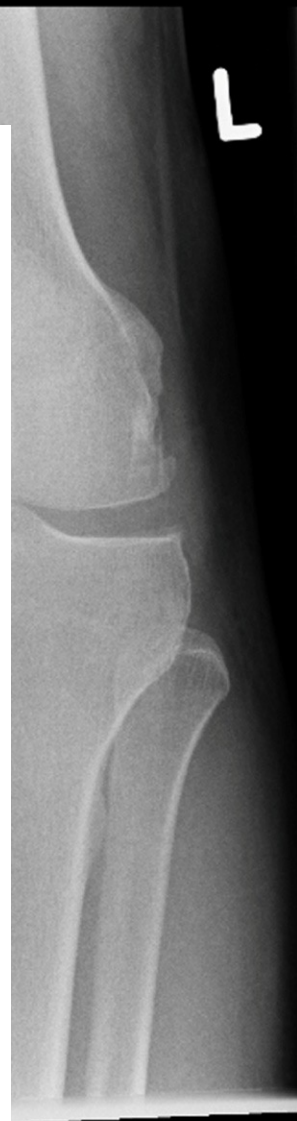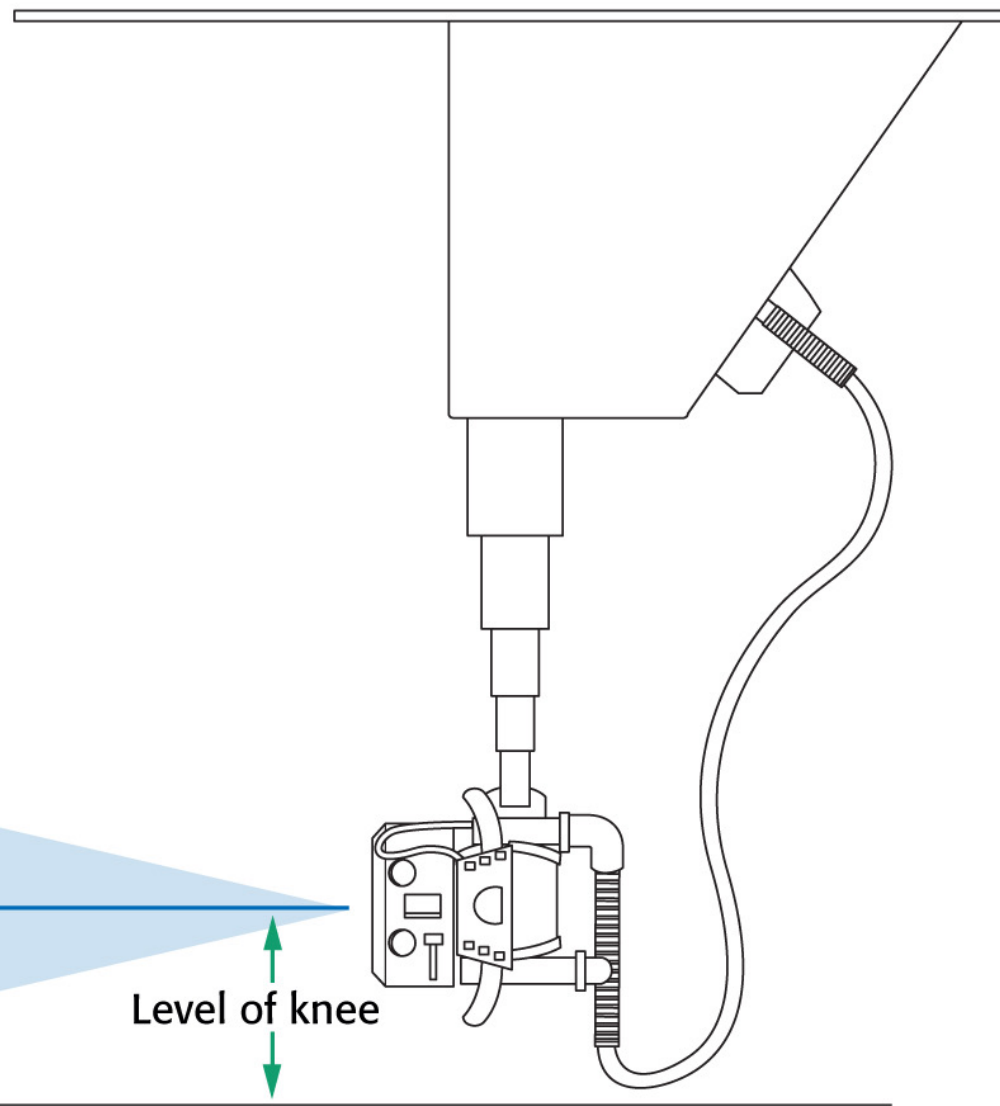
0 - 2 ans : Genu varum gradually decreases

2 - 10 ans : The Genu Valgum is max at 3 years old (girl) and 4 years old (boy). Then it gradually decreases

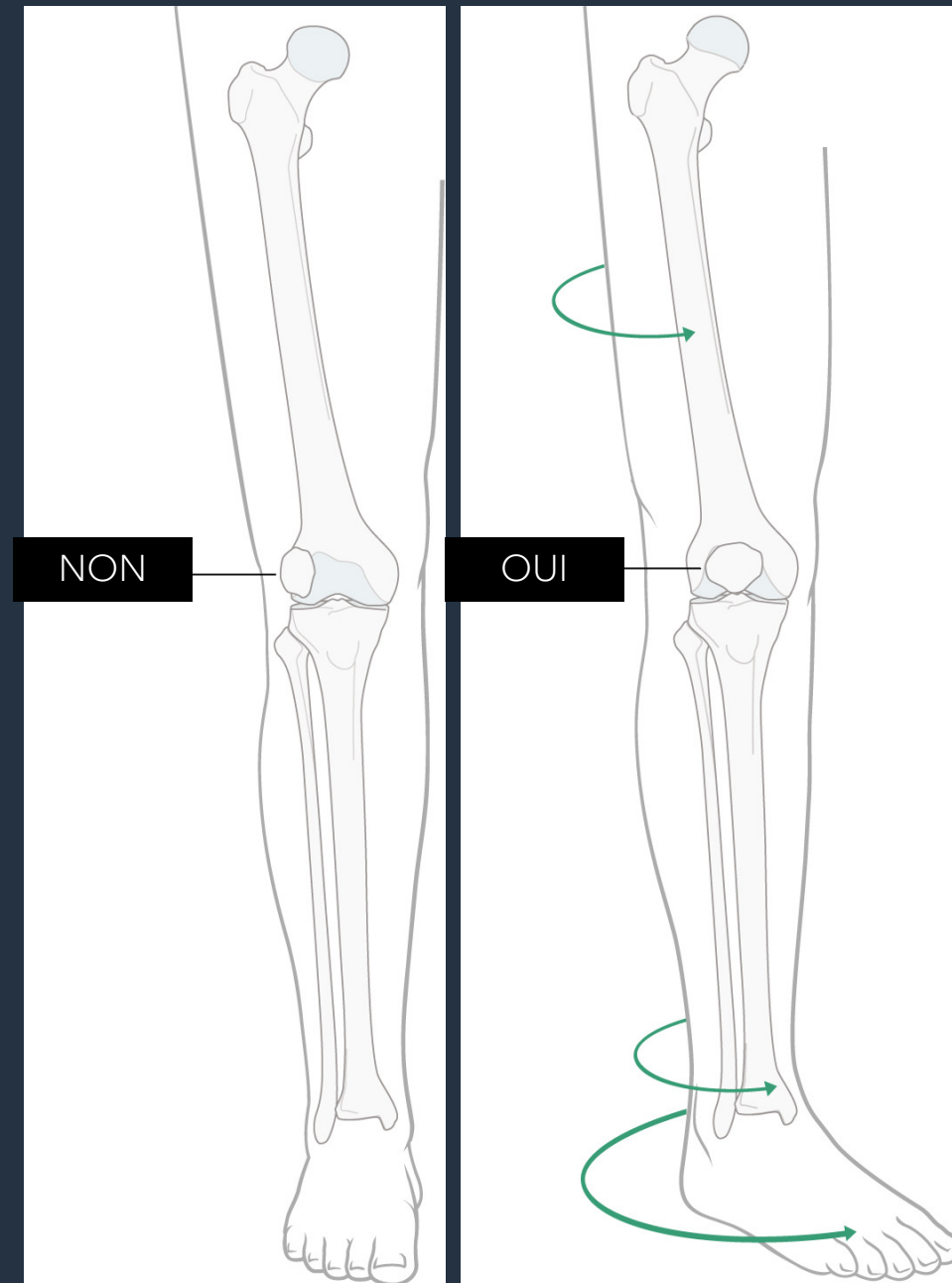
>10 ans : TENDANCY to Genu Valgum (girl), Genu Varum (boy)



Level of knee

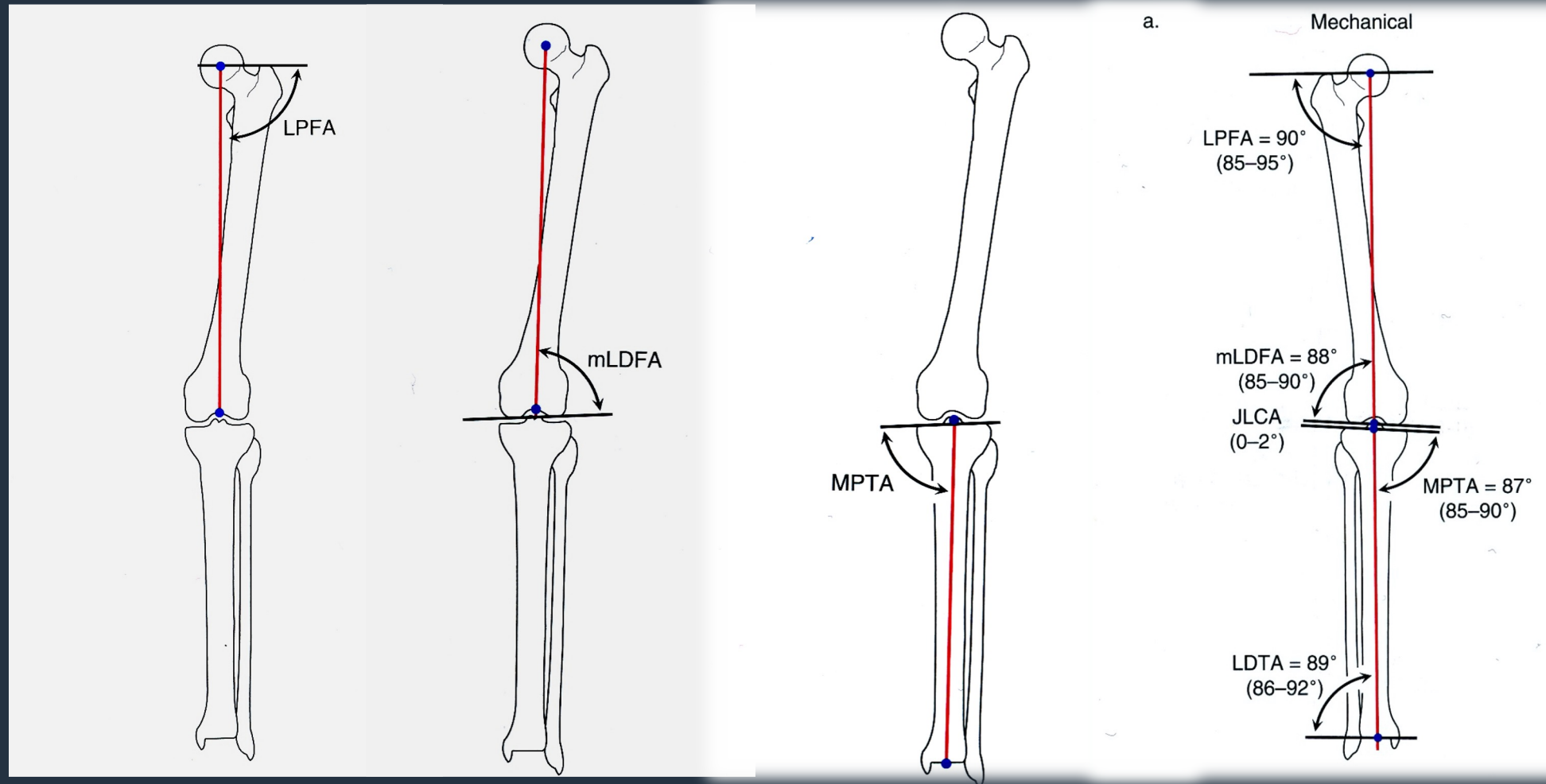


ORIENTATION WHEN SHOOTING



INTERNATIONALE NOMMENCCLATURE

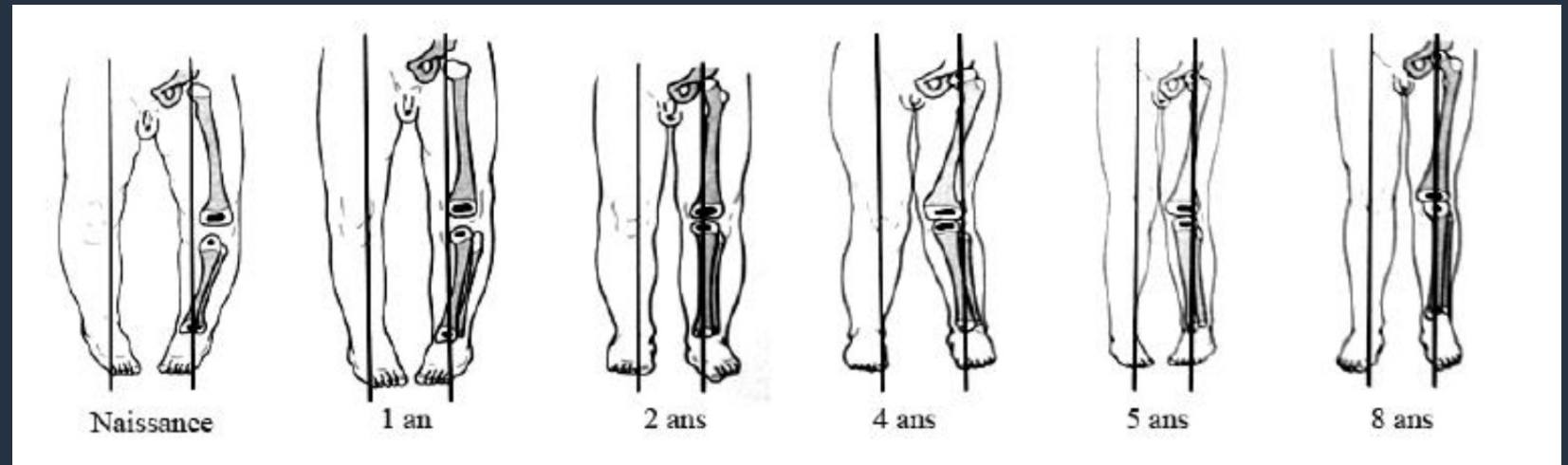
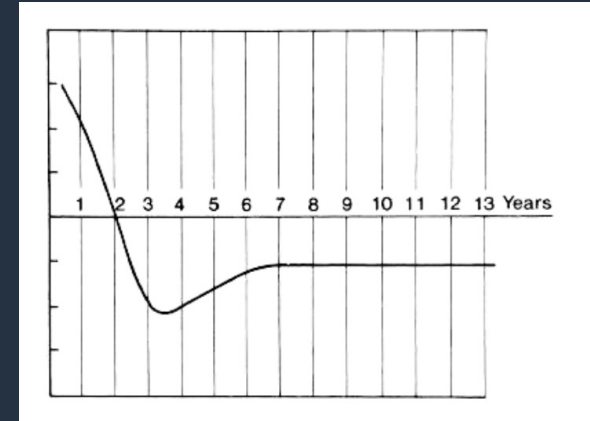
- m : mechanical
- a : anatomical
- L : Lateral
- M : Medial
- P : proximal
- T : tibial
- F : fémoral
- A : Angle



MORPHOTYPE ABNORMALITIES IN THE FRONTAL PLANE

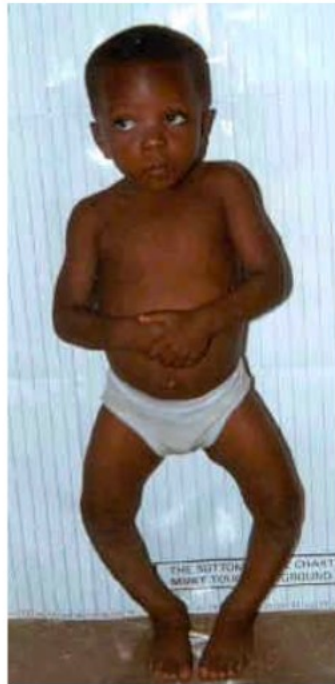The legs axis evolves until the age of 7!

- Genu varum in small children
- Genu valgum under the effect of weight-bearing (acquisition of gait)
- Then stabilization around 7 years old



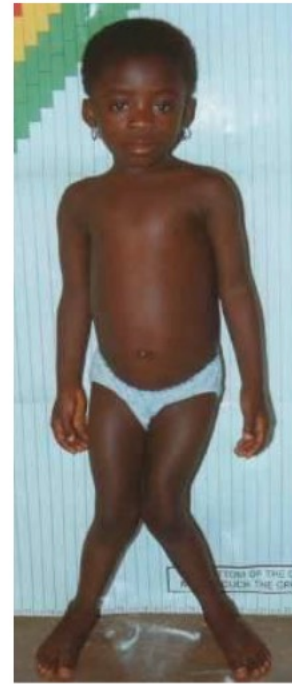MORPHOTYPE ABNORMALITIES IN THE FRONTAL PLANE

Genu varum



Rotules au zénith
Contact intermalléolaire
Ecart intercondylien

Genu valgum

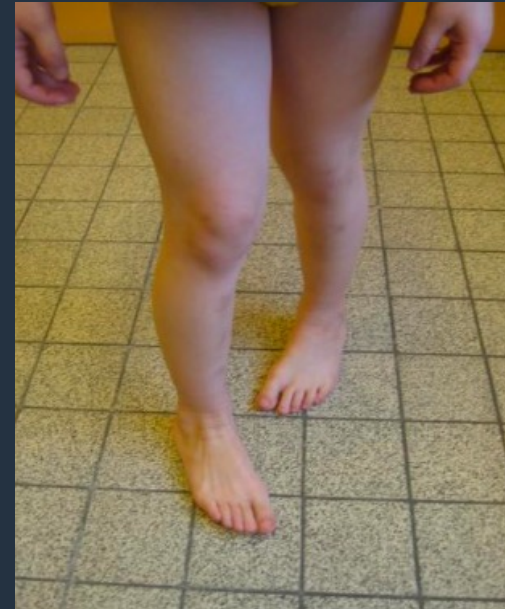


Rotules au zénith
Contact intercondylien
Ecart intermalléolaire

DIFFERENT FROM MORPHOTYPE ABNORMALITIES IN THE HORIZONTAL PLANE

Common reason for consultation

- "Spinning" feet (steps in or out)
- Often related to a femoral or tibial torsional abnormality
- « Heavy » surgical osteotomies sometimes needed



MORPHOTYPE ABNORMALITIES IN THE FRONTAL PLANE



False genu VALGUM
Due to adolescent overweight



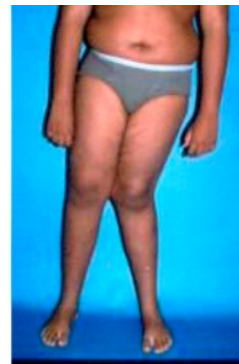MORPHOTYPE ABNORMALITIES IN THE FRONTAL PLANE

Is deviation: _____

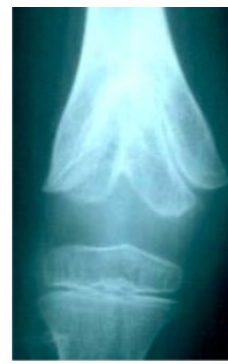- Bilateral
- Symetrique

Is there a cause to the deformation ?

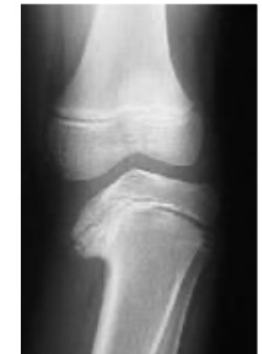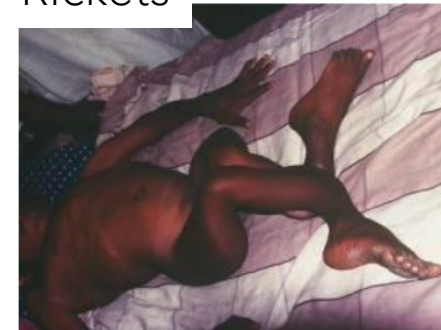
Traumatic



Infection



Rickets



Blount disease

MORPHOTYPE ABNORMALITIES IN THE FRONTAL PLANE

Is deviation:

- Bilateral
- Symetrique

Is there a cause to the deformation ?

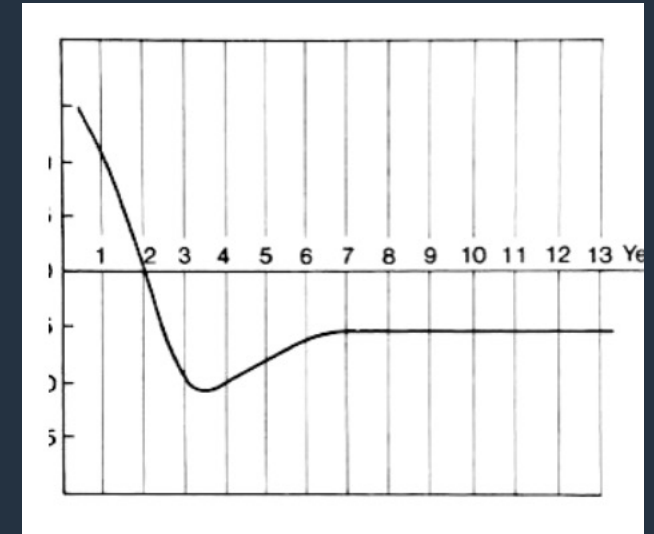
What are the consequences ?

- Falls
- Pain

MORPHOTYPE ABNORMALITIES IN THE FRONTAL PLANE

Most of the time the deviation is :

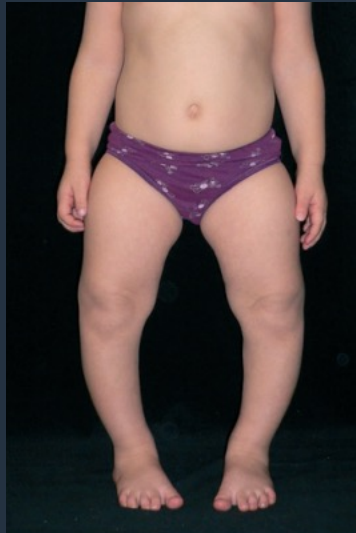- Bilateral & symmetric
- No identified cause
- Not symptomatic / no consequences



FRONTAL MORPHOTYPE IN VARUS

Clinical examination: Intercondylar gap

- Stand, knees extended, knee caps strictly facing
- or small children, easier lying down



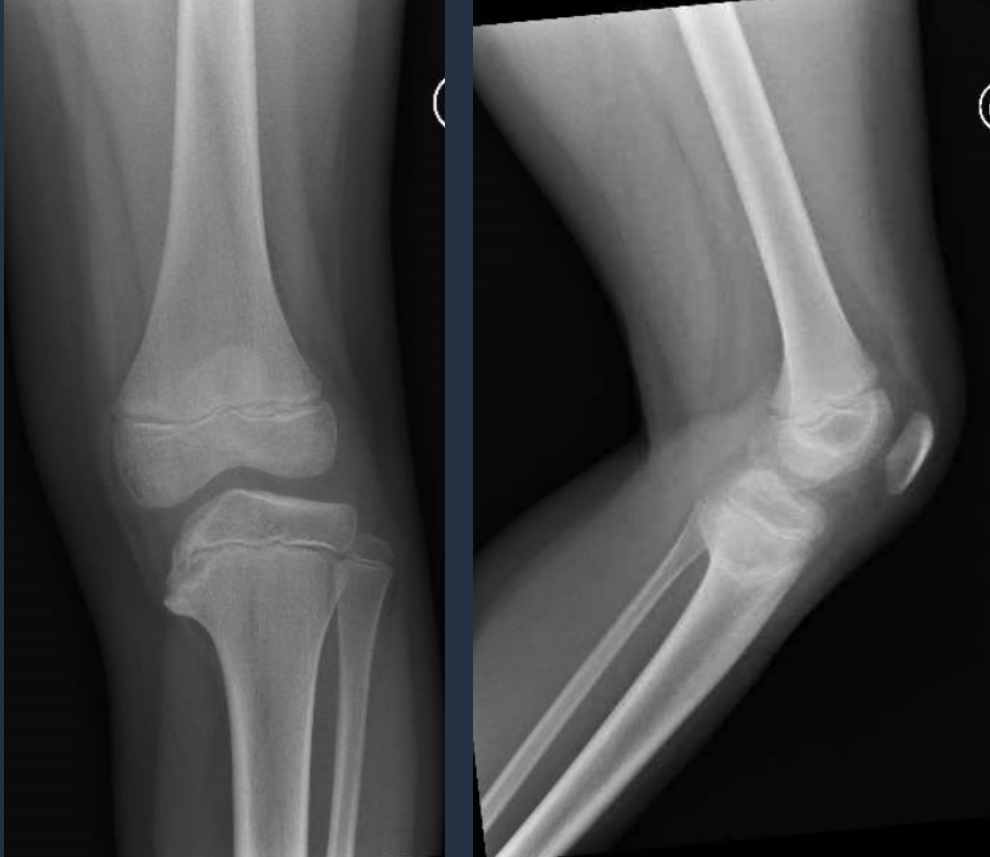ETIOLOGY

- Physiological (<2 years)
- Idiopathic
- Secondary
- Blount's Disease
- Constitutional Bone Disease
- Deficiency rickets, vitamin-resistant
- Post-traumatic stress disorder
- Post-infectious

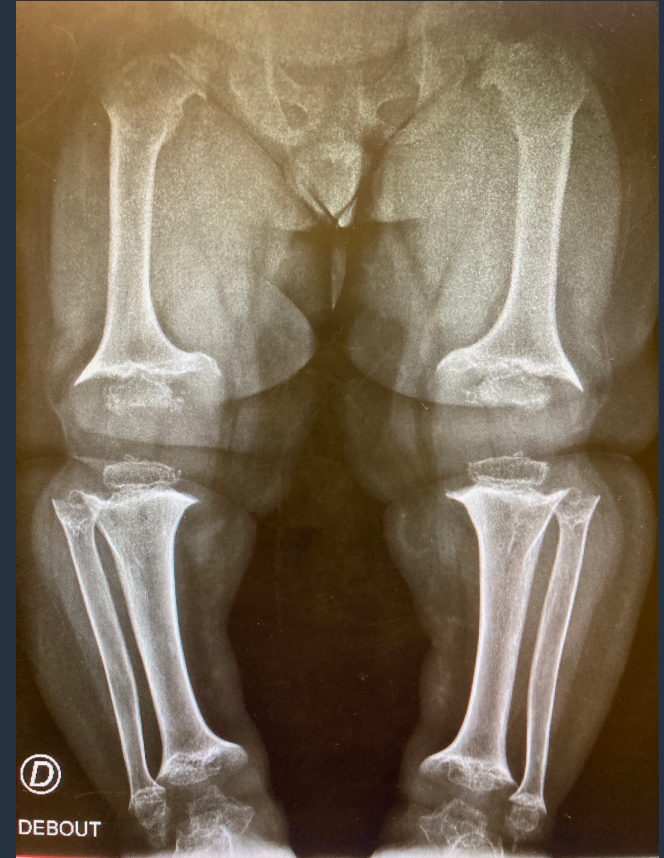* Any asymmetrical varus is a priori pathological

* Any genu varum that continues to worsen after the age of 2 years should be considered pathological.

* In pre-adolescents, a genu varum with an intercondylar distance > 3cm should be considered pathological.



Blount's disease: deformity of the prox and medial epiphysometaphyseal region of the tibia



Achondroplasia: association with short stature

FALSE GENU VALGUM

Trap: False genu varum due to femoral antetorsion and knee recurvatum

=> disappearance of the genu varum in anatomical position, patellas strictly opposite

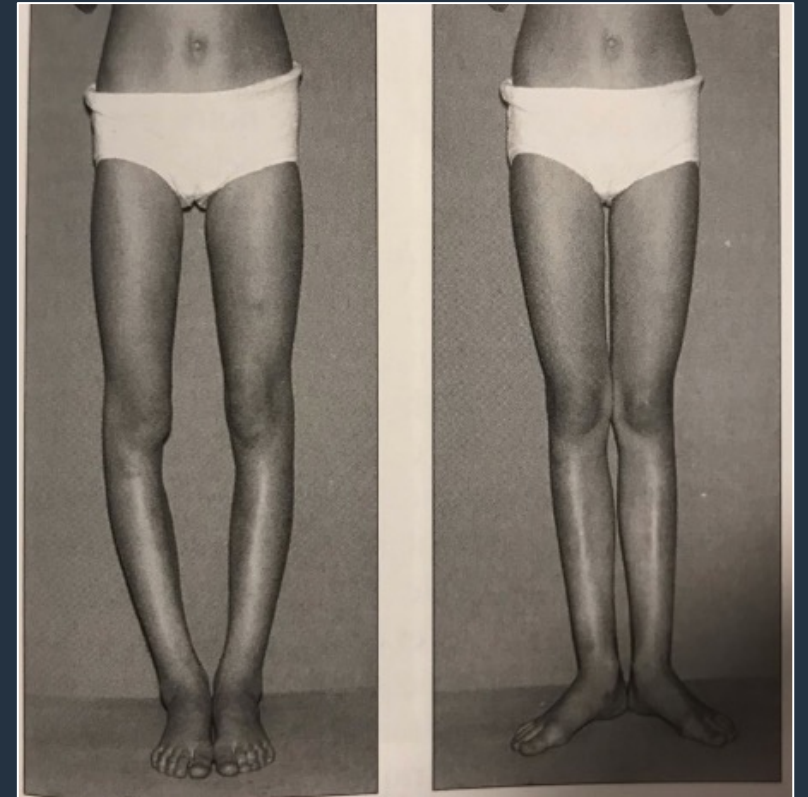
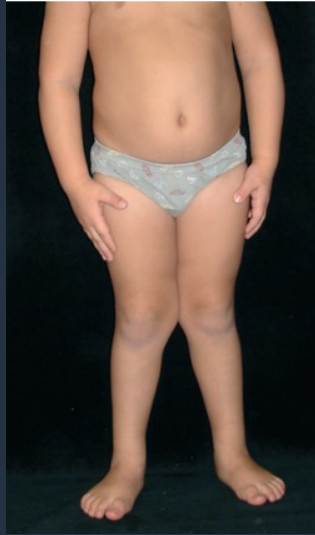

Fig. 11. 2 – Faux genu varum par hyperantétorsion fémorale et récurvatum du genou.

FRONTAL MORPHOTYPE IN VALGUS

Clinical Examination: Intermalleolar Gap

- Stand, knees extended, kneecaps strictly facing
- For small children, easier lying down



- Physiological (3-4 years)
- Idiopathic
- Secondary
- Constitutional Bone Disease
- Deficiency rickets, vitamin-resistant
- Post-traumatic st

- Any asymmetrical defect is a priori pathological.
- Any genu valgum that continues to worsen after the age of 4 should be considered pathological.
- In pre-adolescents, a genu valgum with an intermalleolar distance $> 8\text{cm}$ should be considered pathological
- Trap: false genu valgum of obese children

POST-TRAUMATIC FRONTAL DEFORMITIES

Metaphyseal fracture of the proximal tibia

Growth Cartilage Injury: Epiphysiodesis

- Central total or partial epiphysiodesis

Length unevenness without misalignment

At the knee: varus by fibula growth

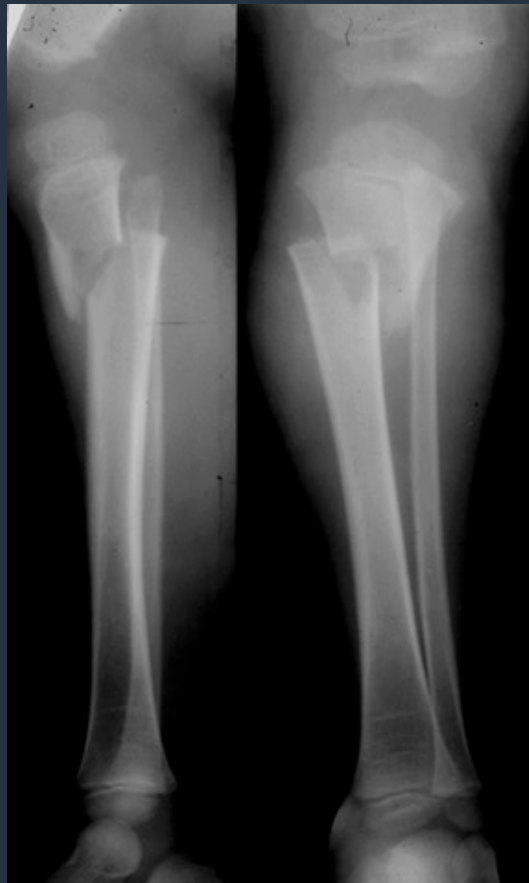- Peripheral epiphysiodesis

Varus or valgus misalignment

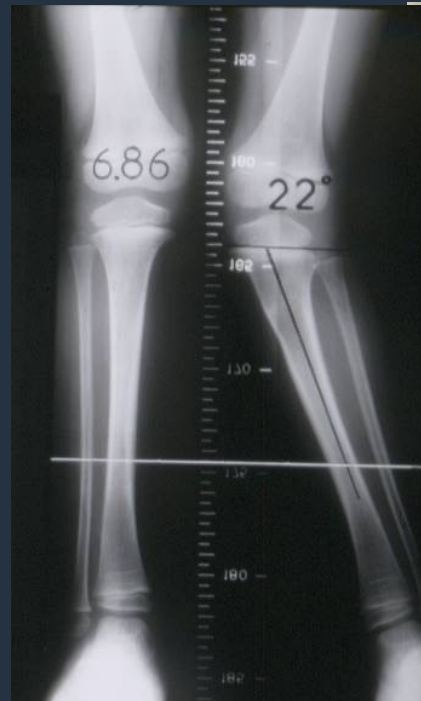Recurvatum

Flexum

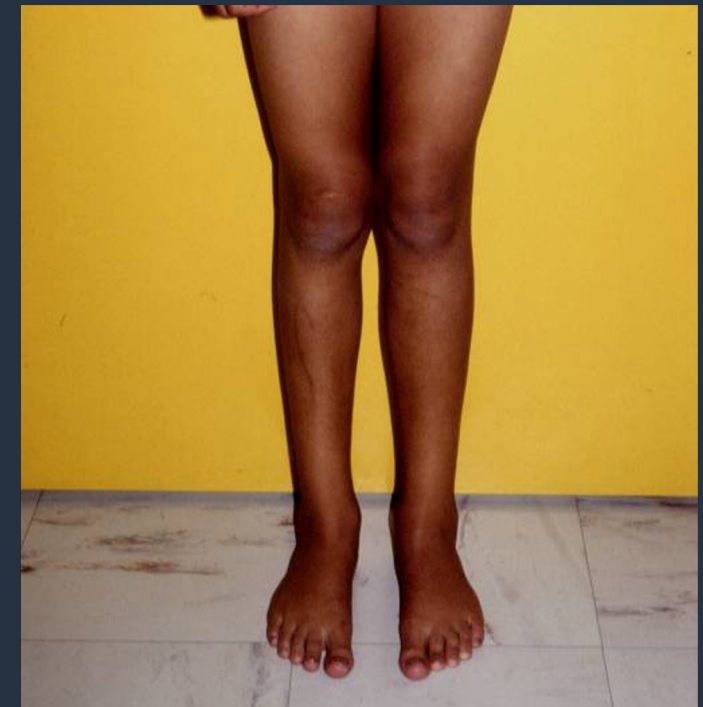
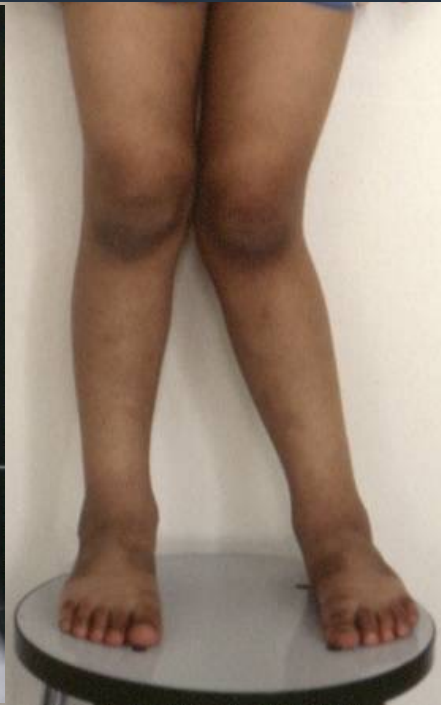METAPHYSEAL FRACTURE OF THE PROXIMAL TIBIA



**Isolated fracture
upper tibia, 4 years**



**Bone healing
Valgus developed in 6 months**



**Spontaneous evolution
+ 5 years**

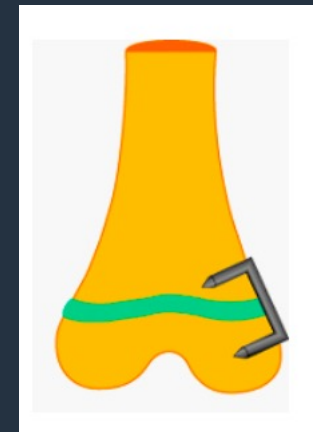
TREATMENT OF FRONTAL DEFORMITIES IN CHILDREN

Physiological axis deviation for age

- no additional examinations
- no treatment (no pathology...)
- explanations of growth
- monitoring

Pathological axis disorder

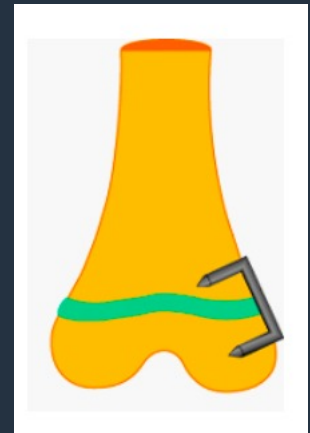
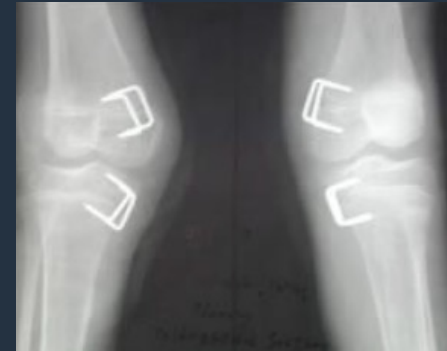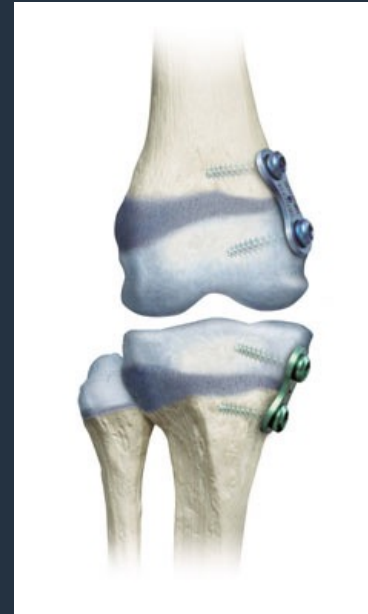
- Hemi-epiphysiodesis at the end of growth
- Etiology treatment



SURGICAL TREATMENT OF FRONTAL DEFORMITIES IN CHILDREN

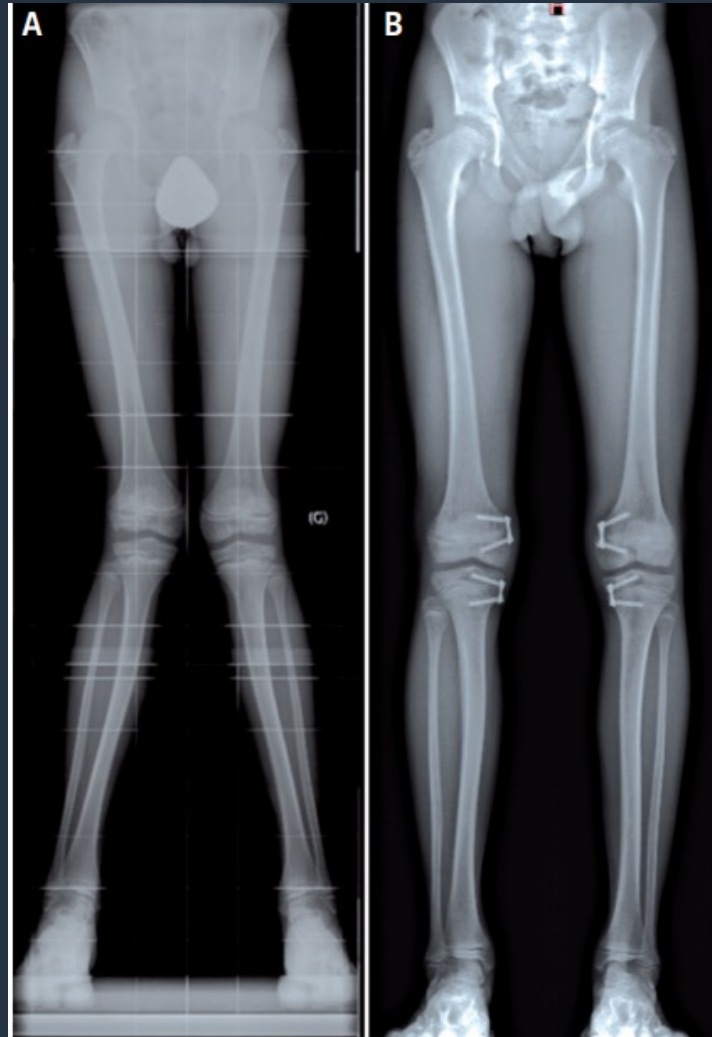
Hemi-epiphysiodesis or figure-8 plate-guided growth

- Femoral and/or tibial valgum genu: internally
- Genu varum femoral and/or tibial: external



After the end of growth, there is no other solution than to do corrective osteotomies

EXAMPLE: SYMMETRICAL IDIOPATHIC GENU VALGUM MODULATION OF GROWTH BY HEMI-EPIPHYSIODESIS



- Indication: Intermalleolar gap > 8 cm
- Bone age: 11 years (girl), 13 years (boy)
- Ablation of the plate once normo-focused

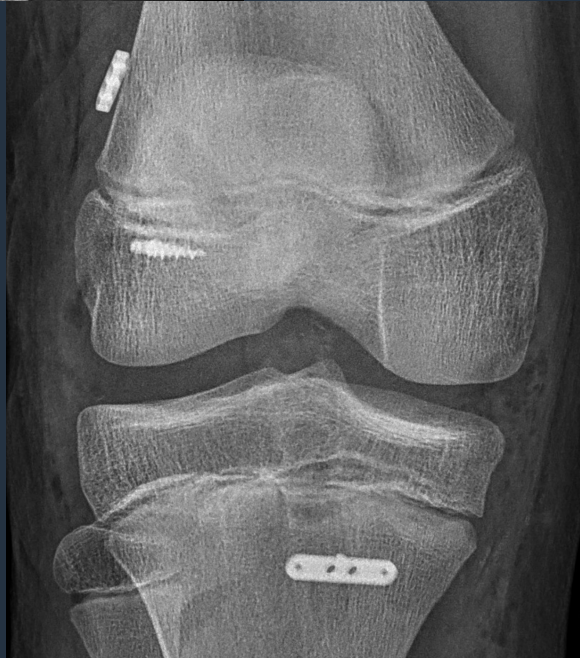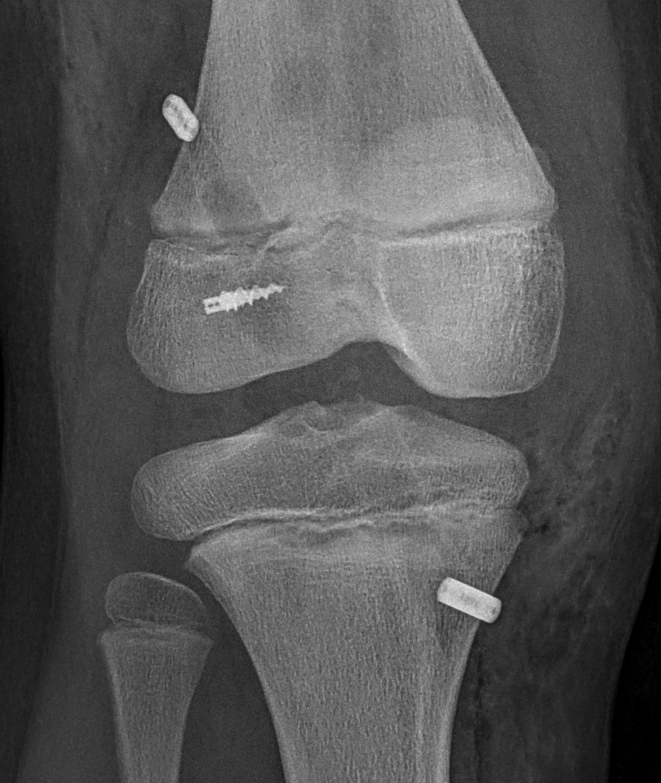Regular monitoring:
Clinical follow-up /6 months
Photographs

IATROGENIC EFFECT OF ACL RECONSTRUCTION CHILDREN / ADOLESCENT ?

ALL / Tenodesis is (for us) required < 18 yo

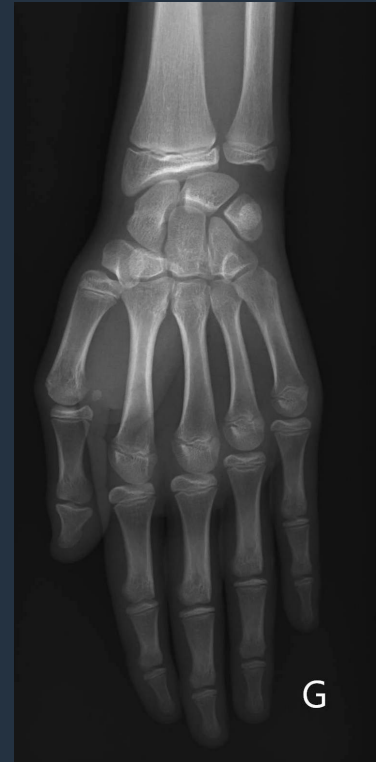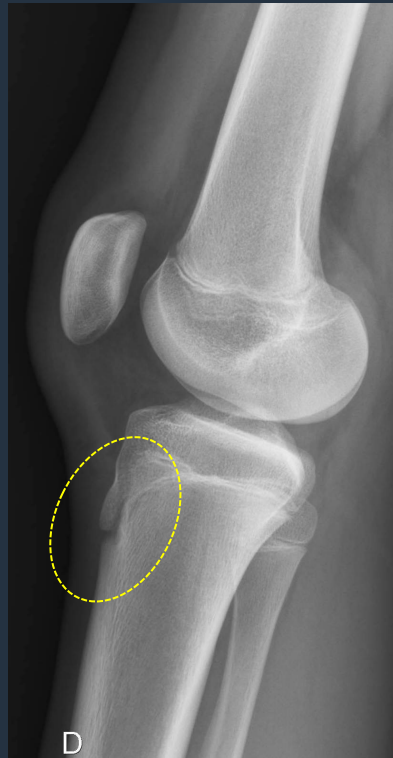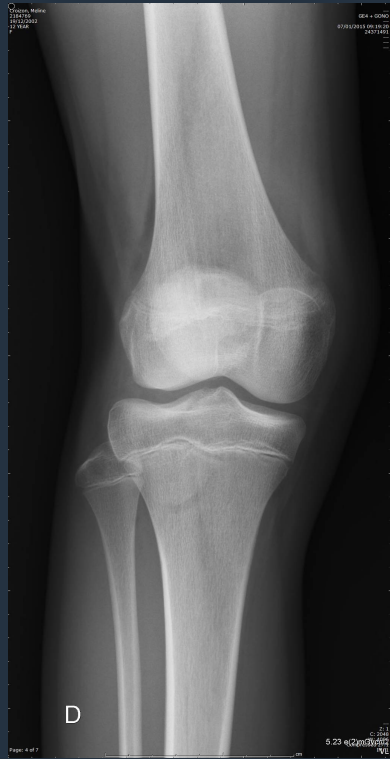We do not graft Antero Lateral Ligament < 12 YO ... but we do a LATERAL TENODIS to avoid Tibial tubercule growth. Disturbance if < 12 YO

... or we go for Mac FL combined ACL -ALL reconstruction intraphyseal femoral reconstruction / over the top



In practice

Quantify the residual growth potential



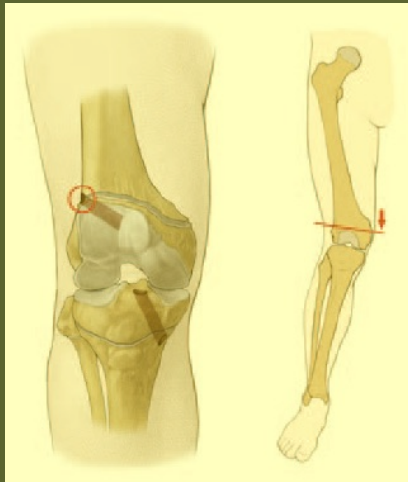
MANDATORY +++

Potential growth disturbances in pediatric ACL reconstructions

4 types of gross complications

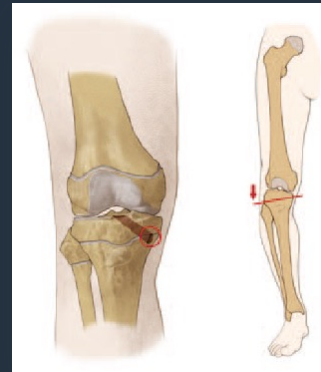N = 354 in the literature

Moksnes, Engebretsen, Seil, KSSTA 2015

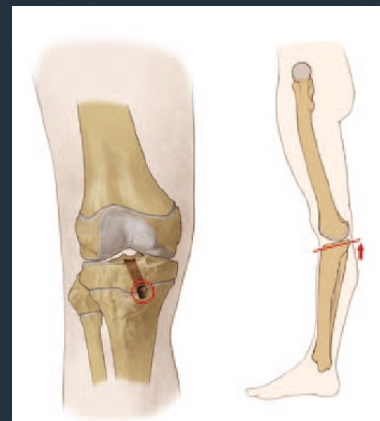


Arrest distal lateral femur physis: valgus knee

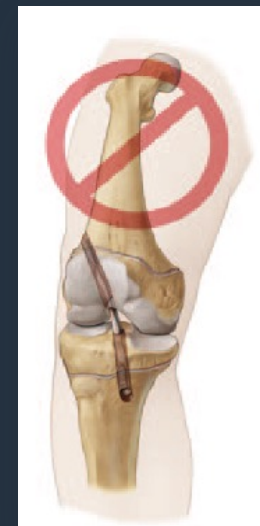Arrest tibial tuberosity: recurvatum



Arrest medial proximal tibial physis: Varus knee



NO transphyseal hardware or synthetic graft



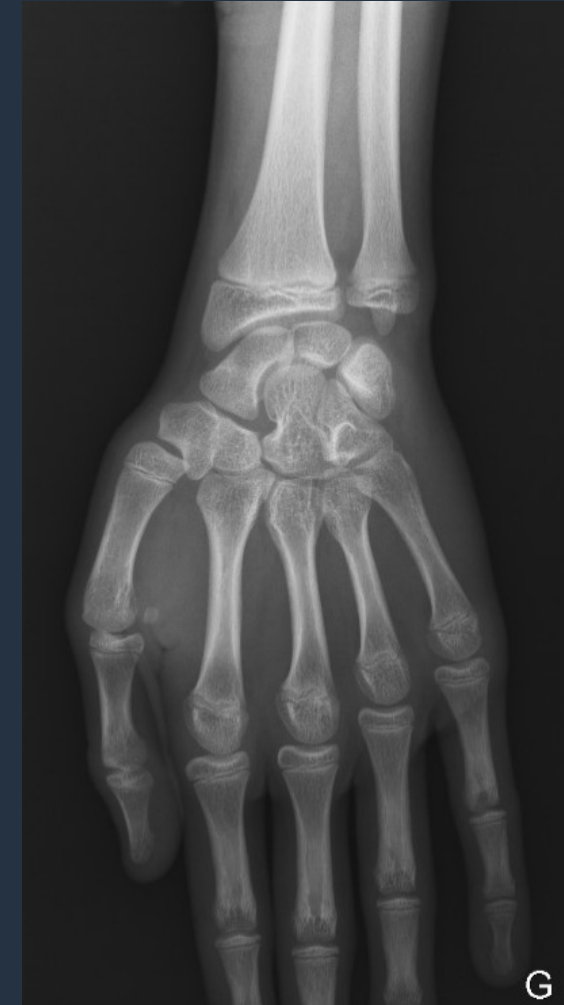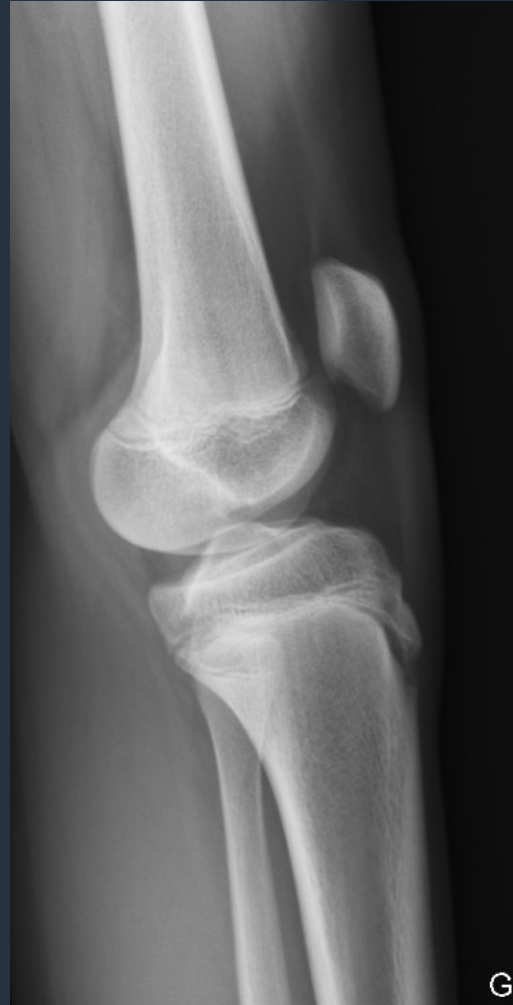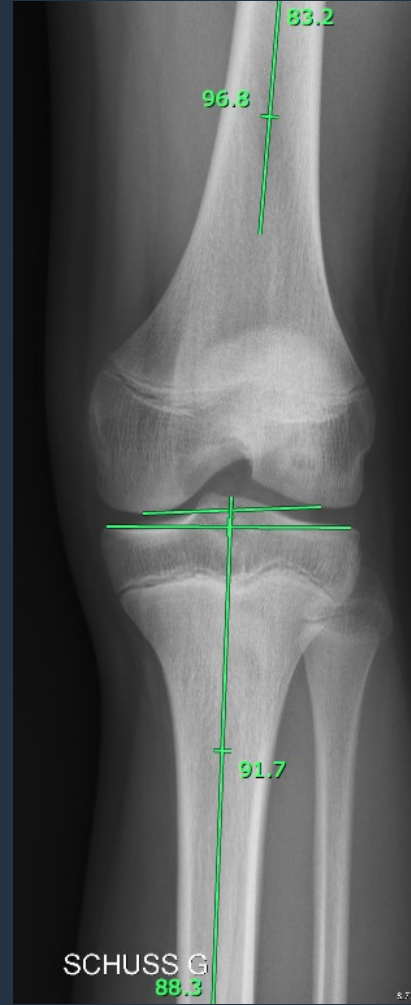
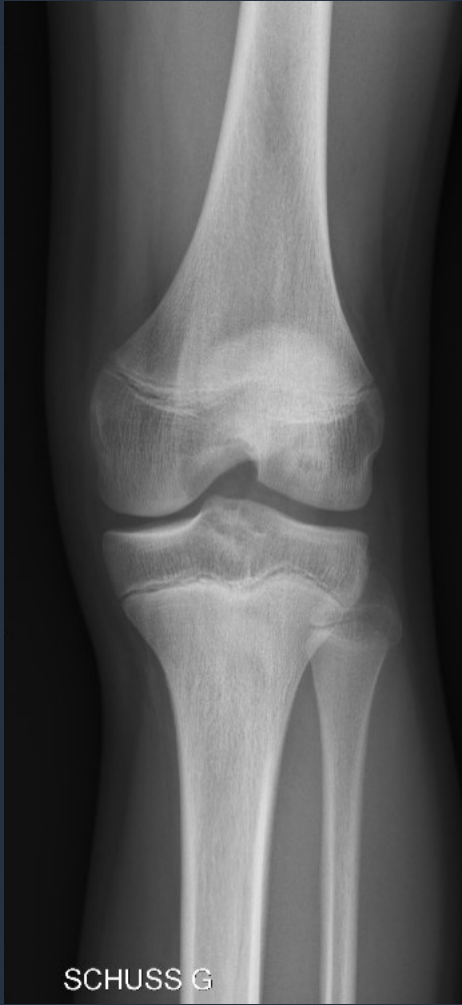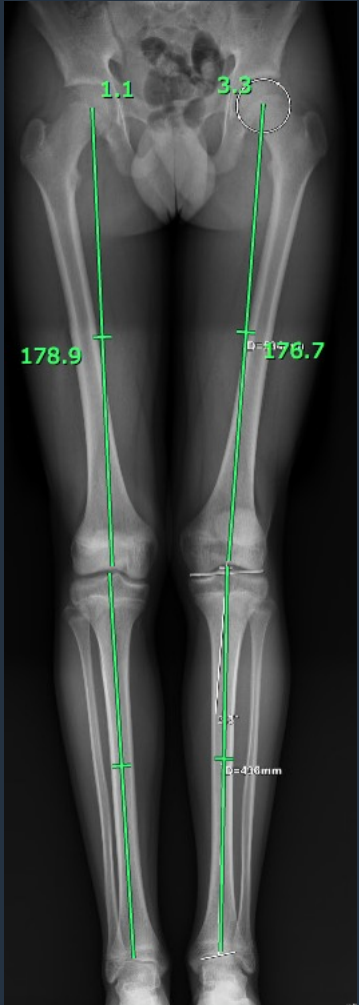
chl.lu

Chotel F, KSSTA 2010

GABIN S - 12 YO / 2015

- 12 YO un 2015
- Left knee injury
- FOOTBALL knee injury , 2 training. & 1 game / week
- LACHMAN ++, ant. Drawer + , « General Hyperlaxity » , PM knee pain (meniscal lesion)

INITIAL X_RAYS : LONG X-RAYS+ OSSEOUS AGE

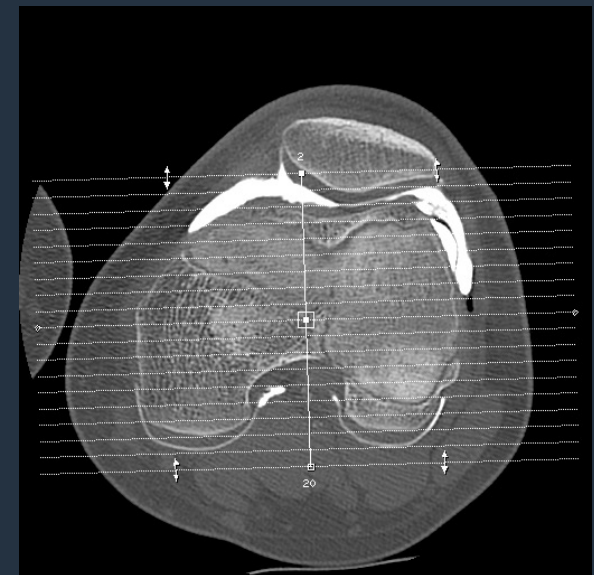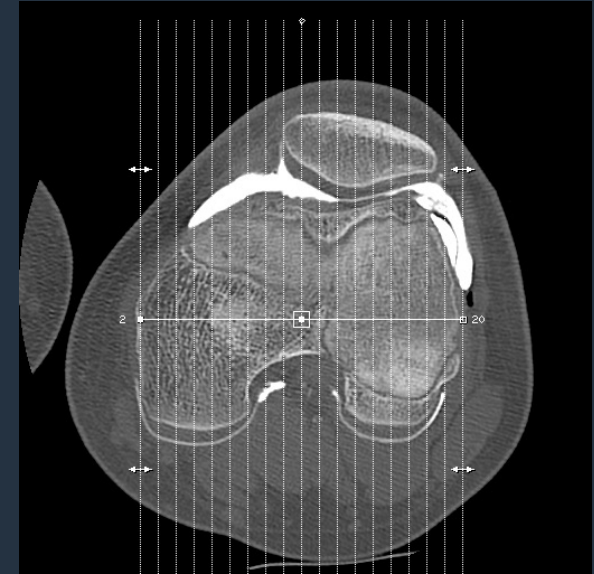


GABIN S / 2015

- 0,5 ° of valgus (HKA)
- Iso lenght
- Osseous age : 12 ½
- 3 months of physion : UNSTABLE & UNABLE to play soccer
- JULY 2015 : ACL-rec w. ST4 Hamstrings + vert. Post men lesion = suture 2 anchors

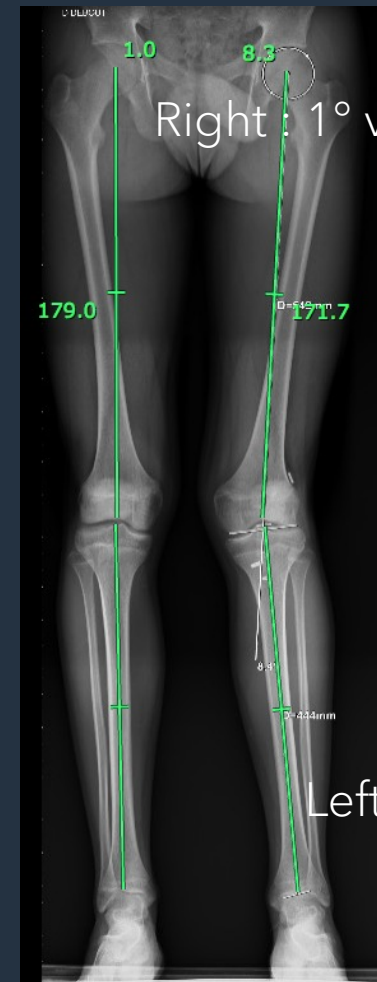
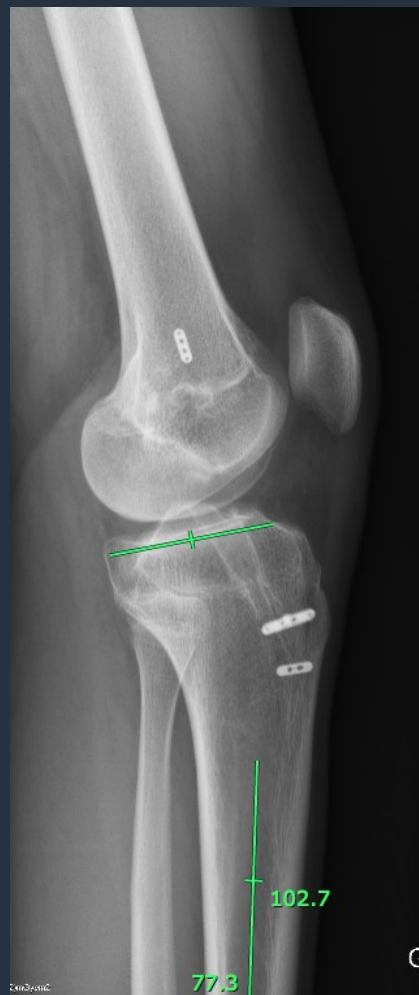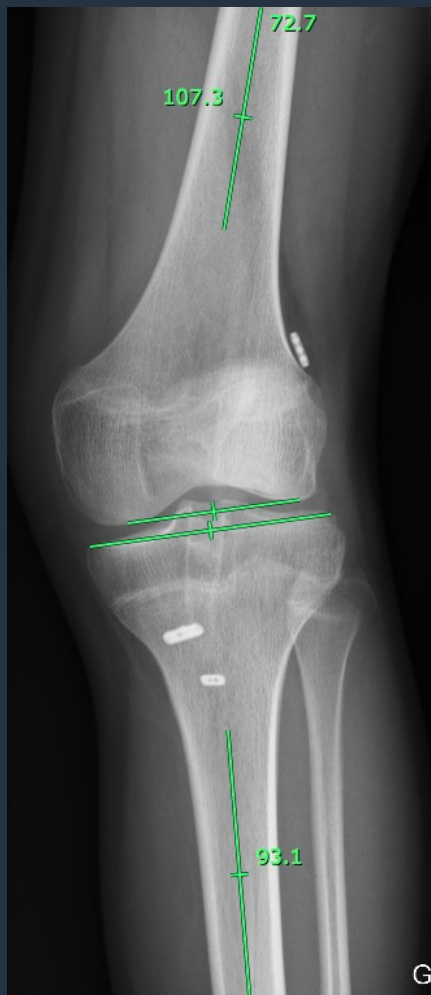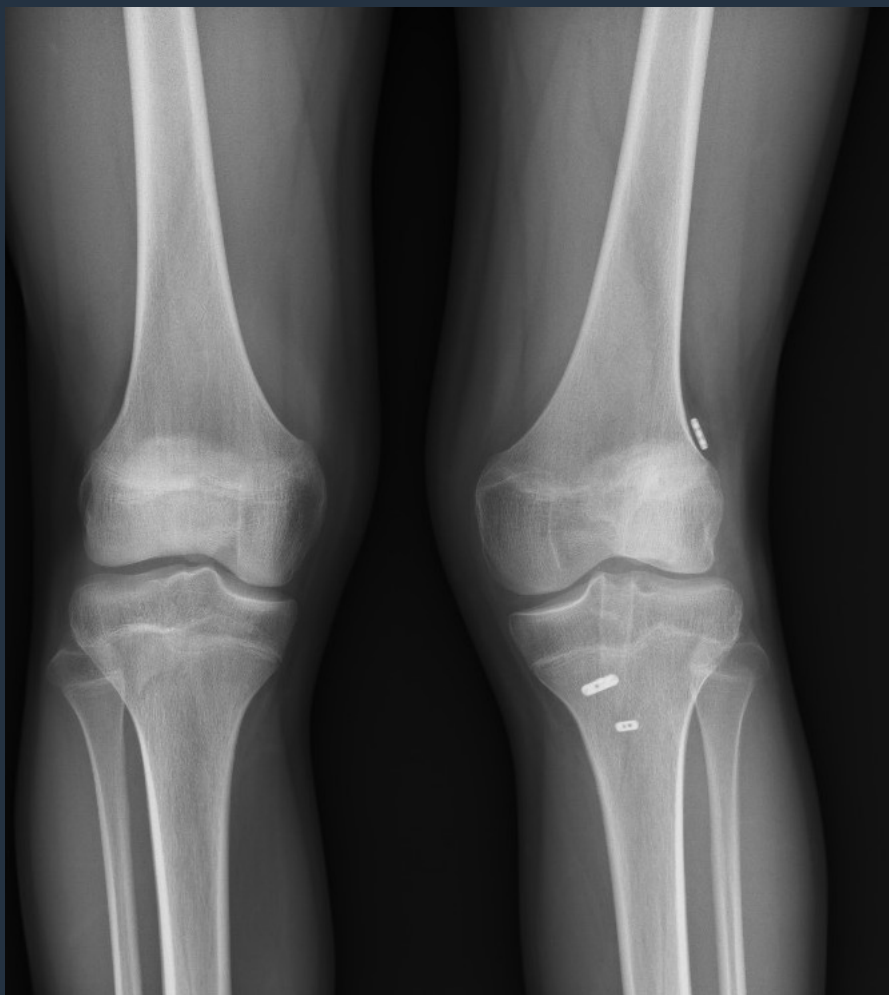
GABIN S / 2017

- Bucket handle of the repaired medial meniscus
- Partiel medial. Menisectomy 2/3 of the meniscal body



X_RAYS SURVEY : 2023 ,

12° of TIBIAL SLOPE



8° RESIDUAL VALGUS


- Correct it or not ?
- Can not play soccer ... but like biking
- Still on survey ...

THE ANTERIOR CRUCIATE LIGAMENT

3 - 5 OCTOBER 2024
LYON CONVENTION CENTRE
www.lyon-knee-congress.com

21^{èmes}

Journées Lyonnaises
de Chirurgie du Genou



SFA
2024

BORDEAUX
PALAIS 2 L'ATLANTIQUE
DÉCEMBRE 11/12/13/14

PRÉSIDENCE DU CONGRÈS :
YACINE CARLIER
NICOLAS GRAVELEAU

SYMPOSIUM
• Régistre instabilité antérieure de l'épaule.
• Abolir l'IBELI chronique DELATTE
• Reprise du sport après LCA.
Benjamin FREYCHET, Corinne CHOUFANI
• SMILE Mini instabilité latérale épicondylienne
du coude
Hubert LENOIR, Patrick GOETTI

www.sofarthro.org



MERCI DE VOTRE ATTENTION BIENVENUS À BORDEAUX-MÉRIGNAC

